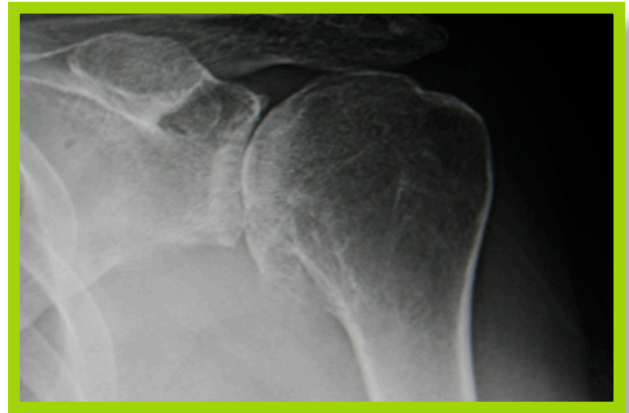
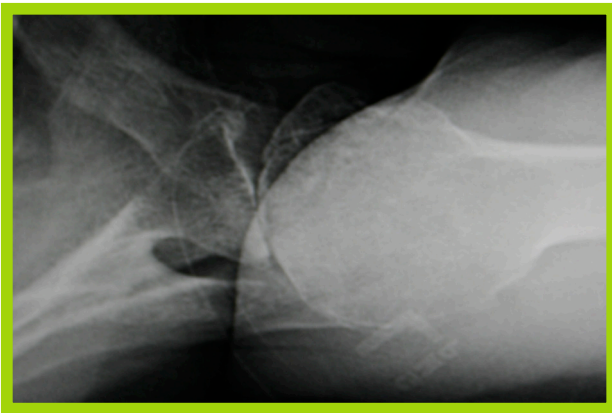


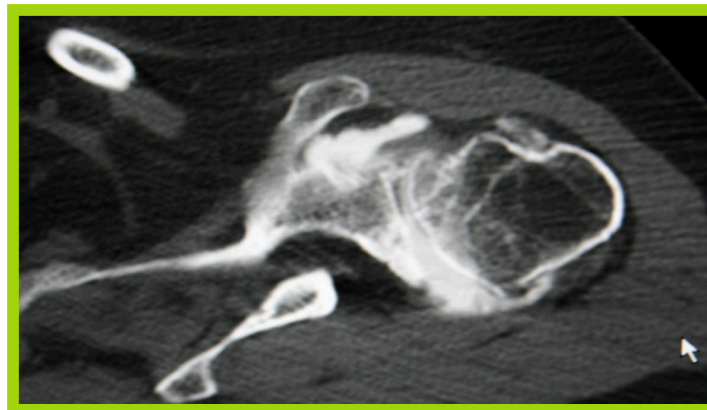
CASE REVIEW: *Shoulder Arthroplasty with Inset Glenoid for B-2 Glenoid with Bone Loss and Posterior Subluxation*

PATIENT HISTORY

61 -year-old right-hand-dominant female with a two-year history of progressive left shoulder 8-9/10 pain and stiffness. She had a previous arthroscopic debridement surgery by another surgeon several years previously. She already failed nonoperative treatments with activity modifications, anti-inflammatory medications, and an intra-articular injection.



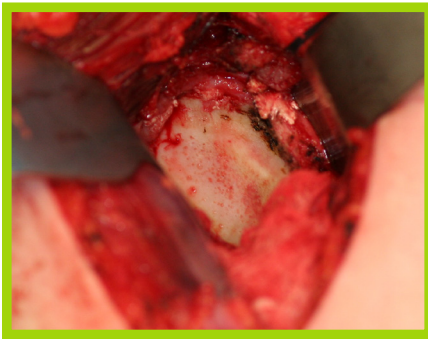
Her x-rays and CT show severe bone-on-bone osteoarthritis with some posterior bone loss and subluxation of the humeral head.



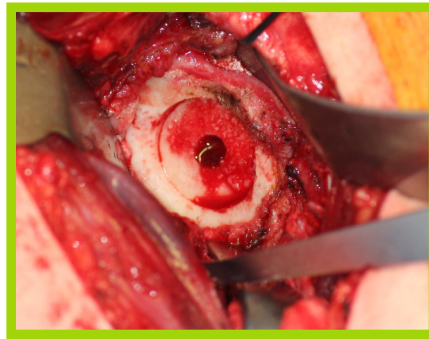CASE REVIEW: *Shoulder Arthroplasty with Inset Glenoid for B-2 Glenoid with Bone Loss and Posterior Subluxation*

OPERATIVE PLAN

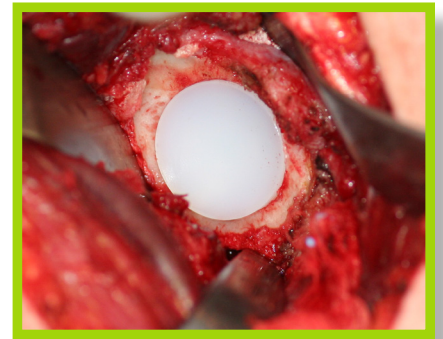
Total shoulder replacement with anterior capsule release, partial labral excision, glenoid resurfacing with inset glenoid implant, and standard humeral implant. Standard postoperative shoulder arthroplasty rehabilitation.



B2 Glenoid



Reamed Inset Pocket



Final Implant

OUTCOME

- 6 months postop
- No pain, excellent motion, improved function.
- *"My shoulder is 95% of normal."*
- ASES 97

